Check for updates

The Laryngoscope
© 2021 The American Laryngological,
Rhinological and Otological Society, Inc.

An Analysis of Tracheostomy Complications in Pediatric Patients With Scoliosis

Swathi Appachi, MD; Jessie Marcet-Gonzalez, CPNP; Jennifer N. Brown, MPAS, PA-C; Julina Ongkasuwan, MD; Elton M. Lambert, MD

Objectives/Hypothesisal: To analyze tracheostomy-related complications in pediatric patients with scoliosis.

Study Design: Retrospective chart review.

Methods: A retrospective chart review of all patients with tracheostomy and scoliosis was performed at a single institution. The charts were reviewed for variables including difficulties with tracheostomy tube changes, poor positioning of tube, abnormal appearance of trachea, and emergency room visits and admissions for complications. Decannulation rates were also identified.

Results: About 102 patients met inclusion criteria, 96 (94.1%) had scoliosis involving the thoracic spine, and 4 had scoliosis involving the cervical spine; 13 (12.8%) patients had documented poor positioning on tracheoscopy; 31 patients (30.3%) had at least one emergency room visit or admission for complications, such as accidental decannulation or bleeding from the tracheostomy; 19 (18.6%) patients required at least one tube change due to poor positioning, with 7 (6.9%) requiring multiple changes; 18 (17.7%) had reported difficulties with home tube changes. Custom length tubes were required in 9 patients (8.8%). The level of scoliosis was not associated with any of these complications. Abnormalities of the trachea, such as tortuosity, obstructive granulomas, or tracheomalacia, were seen in 35 patients (34.3%) on bronchoscopy. Scoliosis repair was performed in 18 patients (17.65%), of which two achieved decannulation. Ten patients (9.8%) overall were decannulated.

Conclusion: A portion of patients with scoliosis who are tracheostomy-dependent have anatomical abnormalities of the trachea and poor positioning of the tracheostomy tube. Decannulation rates are also lower in this population compared to the literature. Further work is required to elucidate if scoliosis predisposes patients toward tracheostomy-related complications.

Key Words: Pediatric, tracheotomy, scoliosis, complications.

Level of Evidence: 4

***Laryngoscope*, 00:1–5, 2021**

INTRODUCTION

Children with long-term tracheostomy tube use can experience many complications including peristomal and suprastomal granulation.[1] The size and length of the tracheostomy tube may influence risk of complications, as poorly fitting tubes may lead to irritation and erosion of the tracheal wall.[2–4] Tracheostomy tubes may not conform well to the airway when there are structural anomalies of the airway. External compression and torsion of the airway from thoracic vessels, chest wall deformities, and scoliosis can influence the anatomy of the tracheobronchial tree.[2,5,6]

Patients with idiopathic and neuromuscular scoliosis can have decreased size of the tracheal and bronchial lumen.[6,7] Spine curvature may decrease the anterior–posterior chest height and increase the risk of anterior wall tracheal compression by the innominate artery or sternum.[7–10] Airway compression due to spine abnormalities can occur anywhere from the thoracic inlet to the mainstem bronchi.[11]

In the special needs population, there is a confluence of patients who require long-term tracheostomy and ventilator dependence and have neuromuscular scoliosis.[12] At our institution, it was anecdotally noted that patients with neuromuscular scoliosis and who have long-term tracheostomy and ventilator dependence appear to have tortuosity of the airway on tracheoscopy, as well as frequent rubbing of the tip of the tube on the tracheal wall due to an imperfect fit. There are some data indicating an increased risk of developing a late tracheo-innominate fistula (TIF) in patients with severe neurologic and neuromuscular disorders, including scoliosis.[10] However, there is a paucity of literature regarding the rate of tracheal complications and need for adjusting the tracheostomy tube size in this population.

In this study, we seek to describe the complications seen with tracheostomy tubes in patients with scoliosis, and if location of scoliosis affects complication rates. We hope to highlight the tracheal abnormalities seen in these patients, and bring some awareness to the

From the Pediatric Otolaryngology - Head and Neck Surgery (S.A., J.M.-G., J.N.B., J.O., E.M.L.), Texas Children's Hospital, Houston, Texas, U.S.A.; Otolaryngology - Head and Neck Surgery (S.A., J.O., E.M.L.), Baylor College of Medicine, Houston, Texas, U.S.A.; and the Head and Neck Institute (S.A.), Cleveland Clinic Foundation, Cleveland, Ohio, U.S.A.

Editor's Note: This Manuscript was accepted for publication on June 29, 2021.

Presented at the ABEA annual meeting, April 7–12, 2021.

The authors have no funding, financial relationships, or conflicts of interest to disclose.

Send correspondence to Swathi Appachi, MD, Cleveland Clinic Foundation, Head and Neck Institute, 9500 Euclid Avenue A71, Cleveland, OH 44195. E-mail: appachs@ccf.org

DOI: 10.1002/lary.29747

Table I.
Patient Characteristics.

Patient Data	N (%)	Mean Age in Years (Range)
Male	50 (49.0)	
Age		11.1 (0.8–18.7)
Tracheostomy		2.7 (0–15)
Neuromuscular disorders	64 (62.7)	
Respiratory failure	32 (31.4)	
Upper airway anomalies	6 (5.9)	
Scoliosis		6.4 (0–16)
Cervical and thoracic	3 (2.9)	
Thoracic	18 (17.6)	
Thoracolumbar	73 (71.6)	
Lumbar	6 (5.9)	
Lumbosacral	1 (1.0)	
Entire spine	1 (1.0)	
Surgical treatment of scoliosis	18 (17.6)	10.4 (4.6–14)
Decannulation	10 (9.8)	5.5 (1.9–10.6)
Underwent direct laryngoscopy with bronchoscopy	95 (93.1%)	8.8 (0.1–18.7)
Ventilator dependent	69 (67.6%)	

otolaryngologist caring for a tracheostomy tube in this special and often fragile patient population.

MATERIALS AND METHODS

A retrospective chart review of all pediatric patients with tracheostomy and scoliosis was approved by the institutional review board at a single tertiary children's hospital, and patient data were deidentified after chart review was completed and data extracted. The electronic medical record was queried using all ICD-10 codes for scoliosis and tracheostomy placement from May 2001 to October 2019. Records were reviewed to ensure the patient had a true diagnosis of scoliosis by imaging or medical professional, and these charts underwent further review by four individuals. Patient data regarding gender, indication for tracheostomy, age at tracheostomy, duration of tracheostomy, location of scoliosis, age at diagnosis of scoliosis, surgical correction of scoliosis, and date of last follow-up were reviewed. Scoliosis severity data were not included as this was not consistently noted in patient charts. Indications for tracheostomy were categorized by presence of neuromuscular (NMD), respiratory disorders, or upper airway anomalies.

Tracheostomy data for each patient were also reviewed, including: difficulty with home tracheostomy changes, tracheostomy tube changes performed due to poor positioning or ventilation, need for custom tracheostomy tube, hospital admission or emergency room visits due to tracheostomy concerns, persistent or recurring high peak pressures on ventilator, operating room visits due to difficulties with the tracheostomy tube, poor positioning on tracheoscopy, development of TIF and achievement of decannulation. Patient charts were also reviewed for documentation regarding any tracheal abnormalities seen on tracheoscopy or direct laryngoscopy with bronchoscopy (DLB).

Fisher's exact test was performed to see if scoliosis surgery was associated with achieving decannulation. This test was also performed to see if there was an association between tracheostomy complications and location of scoliosis.

RESULTS

One hundred and two patients met inclusion criteria for review (Table I). Fifty (49.0%) patients were male and the average age was 11.1 years (range 0.8–18.6 years). The average age at tracheostomy was 2.7 years (median age 0.9 years, range 0–15 years) and the average duration of tracheostomy was 9.8 years. Sixty-four patients (62.7%) required a tracheostomy due to underlying NMD, 32 patients (31.4%) underwent tracheostomy due to respiratory failure, and 6 patients (5.9%) had upper airway anomalies. NMD requiring tracheostomy included cerebral palsy, hypoxic ischemic encephalopathy, traumatic brain injury, central nervous system tumors, muscular dystrophy, or syndromes involving the central nervous system. Respiratory disorders included long-term ventilator dependence for bronchopulmonary dysplasia, chronic lung disease, and lung hypoplasia. Pierre Robin sequence, subglottic stenosis, and tracheomalacia were categorized as upper airway indications for tracheostomy.

Average age at diagnosis of scoliosis was 6.4 years (median age 6 years, range 0–16 years) (Table I). The majority of our patients (73, 71.6%) had thoracolumbar scoliosis, and 18 (17.6%) had scoliosis only of the thoracic spine. Three patients (2.9%) had scoliosis involving the cervical and thoracic spine and 6 patients (5.9%) had scoliosis confined to the lumbar spine. One patient (1.0%) had lumbosacral scoliosis and one patient (1.0%) had scoliosis of the entire spine. Eighteen (17.6%) patients underwent surgery to correct their scoliosis at the

Table II.
Tracheostomy-Related Complications.

Complication	N (%)	Association With Site of Scoliosis	Mean Age at Initial Presentation in Years (Range)
Emergency room visit/hospital admission	31 (30.3)	No ($P = .20$)	7.9 (0.5–17)
Tube changes for poor ventilation/positioning	19 (18.6)	No ($P = .15$)	8.3 (0.1–18.7)
Difficulty with home tube changes	18 (17.7)	No ($P = .87$)	10.2 (6–17)
Operating room visit	14 (13.7)	No ($P = .54$)	9.1 (0.1–17)
Need for custom tube	9 (8.8)	No ($P = .37$)	11.4 (0.2–17)
High peak pressures on ventilator	8 (7.8%)	No ($P = .40$)	6.4 (2–12)
Tracheo-innominate fistula	0 (0)	N/A	N/A

Table III.
Tracheal Abnormalities Noted on Direct Laryngoscopy and Bronchoscopy.

Abnormality	N (%)	Mean Age in Years (Range)
Tracheomalacia	16 (16.8)	6.0 (0.25–15.1)
Tortuosity	10 (10.5)	8.5 (0–17)
Obstructive granuloma	3 (3.2)	10.1 (7–13.8)
Tracheal stenosis	1 (1.1)	10.0
Suprastomal collapse	1 (1.1)	7.0
Tracheal sleeve	1 (1.1)	0
Short trachea	1 (1.1)	0.5

average age of 10.4 years (4.6–14 years). Ten patients (9.8%) achieved decannulation, of which two had undergone surgical repair. The average age at decannulation was 5.5 years (1.9–10.6 years). Out of the 10 patients who achieved decannulation, two had a history of tracheoesophageal fistula, five had cardiac or respiratory indications for tracheostomy, and three had NMD such as cerebral palsy or nemaline myopathy. There was no association between surgical repair and decannulation ($P = 1.00$). At the time of last follow-up, 69 patients (67.6%) were ventilator-dependent.

Thirty-one patients (30.3%) had at least one emergency room visit or admission for tracheostomy issues, such as accidental decannulation or bleeding from the tracheostomy site (mean age 7.9 years at presentation, range 0.5–17 years) (Table II). Eighteen patients (17.7%) had reported difficulties with at home tracheostomy tube changes (mean age 10.5 years at presentation, range 6–17 years). Fourteen patients (13.7%) required a nonroutine operating room visit due to tracheostomy-related issues, such as poor ventilation or bleeding (mean age 9.1 years at presentation, range 0.1–17 years). Eight patients (7.8%) had high peak pressures on the ventilator (mean age 6.4 years at presentation, range 2–12 years). No patients developed TIF. Thirteen patients (12.8%) had documented poor tracheostomy tube positioning on tracheoscopy. Nineteen patients (18.6%) required at least one tracheostomy tube change, defined as requiring a change in tube length or type of tube due to granulation tissue, backwalling, or poor ventilation (mean age 8.3 years at first tube change, range 0.1–18.7 years). Seven (6.9%) required multiple tube changes. Of note, the standard tracheostomy tube initially placed at our institution is a neonatal or pediatric Bivona, tight to shaft, silicone tube. Nine patients (8.8%) required a custom-length tracheostomy tube (mean age 11.4 years at placement, range 0.2–17 years). On statistical analysis, when these complications were sub-stratified by location of scoliosis, there was no association between the location of scoliosis or tracheostomy-related complication (Table II).

Ninety-five of the 102 patients in this study underwent at least one DLB at some point during the study period (93.1%), with the most recent DLB being performed at an average age of 8.8 years (range 0.1–18.7 years) (Table I), and at a mean time of 5.2 years after tracheostomy. Of these patients, 71 underwent DLB for routine surveillance after placement of tracheostomy tube (74.7%). Of those who underwent DLB, tracheomalacia was noted in 16 patients (16.8%, mean age 6.0 years at presentation, range 0.25–15.1 years) (Table III). Ten patients were found to have tortuosity of the trachea (10.5%, mean age 8.5 years at presentation, range birth—17 years) (Figure 1), and 3 had obstructive tip granulomas (3.2%, mean age 10.1 years at presentation, range 7–13.8 years). Tracheal stenosis, suprastomal collapse, tracheal sleeve, and a short-appearing trachea were also each seen in one patient on bronchoscopy (Table III).

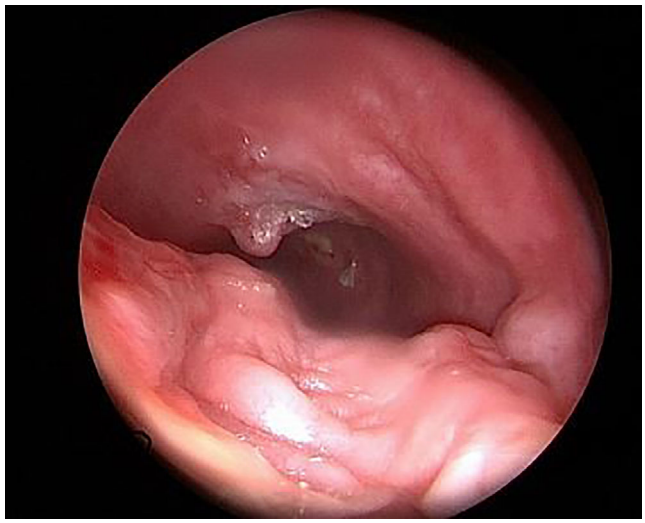

Fig. 1. Bronchoscopy on a patient with scoliosis demonstrates a tortuous trachea with granulation and possible erosion. [Color figure can be viewed in the online issue, which is available at www.laryngoscope.com.]

DISCUSSION

In this study, a portion of pediatric patients with scoliosis and long-term tracheostomy experienced tracheostomy-related difficulties. Most tracheostomy-related complications occurred, on average, at ages older than the mean age at scoliosis diagnosis (Table II). Almost a third of our population (30.3%) required an emergency room visit or hospital admission for reasons such as accidental decannulation or bleeding, and 15.7% were taken to the operating room for indications such as bleeding or obstructive granulation tissue. About 19.6% of patients underwent one or more tube changes due to backwalling, granulation tissue, or poor ventilation. Custom tracheostomy tubes are sometimes considered in patients with granulation tissue, tracheomalacia, or unique anatomy[13]; in this population, 8.8% of patients required a custom-length tube for these issues. Because tracheal abnormalities, such as decreased size of the tracheal lumen, tracheal compression by the innominate arteries, or a tortuous trachea can be seen in patients with neuromuscular scoliosis,[6–8] the above complications are ostensibly due to the repeated contact of the tube or cuff against the trachea due to an inadequate conformation of the tube to the airway. Interestingly, however,

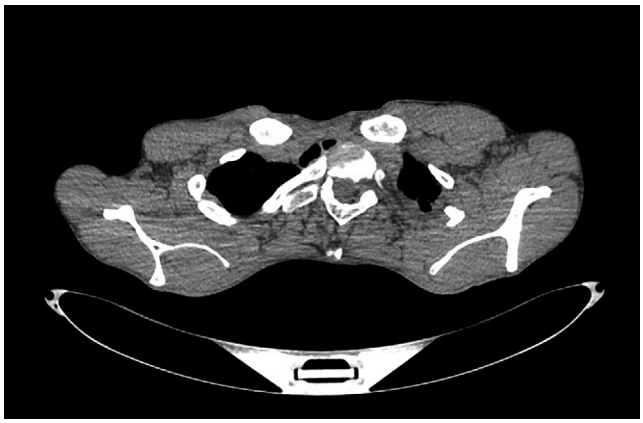

Fig. 2. Axial computed tomography scan of the thorax in a patient with scoliosis demonstrates a deviated trachea that is compressed between the innominate artery and the spine.

poor positioning of the tracheostomy tube on tracheoscopy was noted only in 12.8% of patients. This might be due to a lack of documentation and an imperfect fit of the tube may be underrepresented in this study.

In analyzing the literature for pediatric tracheostomy-related complications, rates of granulation range from 20.4% to 26%.[14–16] In this study, stomal granulomas were not consistently documented but obstructive granulomas at the tip of the tube were found in 3.2% of patients, which is likely due to under-reporting on documentation (Table III). The rates of hemorrhage and accidental decannulation in the literature range from 2.5% to 4.8% and 5.6% to 12.4%,[14,16] respectively, and although these individual rates were not studied in our population, 31.3% of patients required an emergency room visit or hospital admission for reasons including these complications. Reported rates of air leak with impact on ventilation occurring at a rate of 0.4% to 4.9%.[15,16] Although this specific ventilator complication was not analyzed in this study, 7.8% of patients had high peak pressures, potentially due to positioning of the tube. A TIF rate of 1.5% was reported in a systematic review analyzing 49 studies[15]; this complication was not seen in our population.

To prevent these complications in this population, surveillance DLB should be performed on a routine basis. Studies analyzing this procedure in all patients with long-term tracheostomy demonstrated rates of 55% to 61% of airway findings or intervention, including need for debridement of granulation or tube exchange.[17–19] Abnormalities were found even in patients who were not experiencing any difficulties. The American Thoracic Society Consensus Statement for children with chronic tracheostomy recommends rigid or flexible bronchoscopy every 6 to 12 months for these reasons.[20] Thus, if children with scoliosis and long-term tracheostomies are indeed predisposed to increased frequency of complications, a strong effort should be made to perform routine surveillance DLB in this population. If patients cannot go to the operating room for a DLB, then flexible tracheoscopy in the office should at least be performed routinely to assess for fit of the tube, granulation, or changes in the trachea.

We had hypothesized that location of scoliosis may be associated with tracheostomy-related complications. However, on statistical analysis, no such associations were seen (Table II). The majority of patients (73, 71.6%) had thoracolumbar scoliosis, whereas the other groups were much smaller (Table I). Thus, the number of patients in the other groups may have been too low to see a statistically significant association between scoliosis site and complications in this study.

The most commonly noted tracheal anomaly in this population was tracheomalacia (16.8%). Interestingly, tortuosity was noted in only 10.5% of patients, despite almost all patients (94.1%) having curvature of the thoracic spine. Additionally, only 3.2% of patients were noted to have obstructive granulomas. Despite evidence in the literature of tracheal compression by the innominate artery or sternum in patients with scoliosis or neuromuscular disorders (Figure 2),[7,21,22] tracheal stenosis was only present in one patient, and vascular compression of the trachea was not noted in any patients. This may be due to lack of clear documentation differentiating between intrinsic tracheomalacia versus extrinsic compression. Additionally, not all patients in this study underwent DLB, and moreover, these tracheal abnormalities seen on DLB are likely underestimating their presence due to inconsistencies in documentation.

The development of late TIF has also been reported in patients with severe NMD, including scoliosis, due to erosion of the trachea by a long-term tracheostomy tube in patients whose innominate arteries are intimately in contact with the airway.[21,23] Although was not observed in our study, routine bronschoscopy and careful examination for tracheal stenosis or tracheomalacia from innominate artery compression and for erosion and granulation tissue in this population is necessary to prevent this feared complication. Additionally, studies demonstrating the development of late TIF in patients with NMD suggest that there is an increased risk of this if the sterno-cervical spine distance (SCD) (distance from the anterior cervical spine to the posterior sternum) is less than 20 mm.[9,10] Because decreased SCD is often seen in patients with scoliosis, if these patients present with bleeding from their tracheostomy, obtaining imaging on these patients to assess SCD may be helpful in decision-making regarding surgery to prevent TIF.[9,10,24]

The decannulation rate in this study was 9.8%. This is lower than the rates cited for all pediatric patients with tracheostomies, which range from 31% to 75%.[25,26] Additionally, data from our institution examining all tracheotomy patients who underwent decannulation from 2002 to 2011 demonstrated a decannulation rate of 50.2%. On average, patients studied from this population underwent tracheostomy at a slightly younger age (18.2 months vs. 2.7 years) and were tracheostomy-dependent for a much shorter time (29.4 months vs. 9.8 years) than in our study.[27] This large difference in decannulation rate within the same center is likely due to the majority of the patients in our study having underlying NMD (62.7%) and requiring long-term ventilation (67.6%). Moreover, of the 10 patients decannulated in this study, seven of them had the tracheostomy placed initially for indications other than NMD, such as cardiac or respiratory disorders.

Many studies from other institutions have also shown that neurologic comorbidities are a risk factor for ongoing need for tracheostomy.[14,28–30] Thus, the presence of scoliosis itself is unlikely to be related to lower decannulation rate, and this is also demonstrated by the fact that of the 18 patients in this study who underwent corrective spine surgery, only 2 were decannulated.

There are a few limitations to this study. It is retrospective in nature and thus some data retrieval was incomplete as it depended on documentation. For instance, tracheostomy-related complications may not always have been noted sufficiently in the medical record. Similarly, presence of tracheal abnormalities may be underreported as well, especially because not all patients underwent routine surveillance direct laryngoscopy and bronchoscopy. Additionally, only the scoliosis patient population at this center was reviewed for tracheostomy-related complications. However, it is important to note that these can also occur in patients with complex NMD and long-term tracheostomy dependence without scoliosis.[14–16] Therefore, based on the results of this study, one cannot conclude that complications occur at a higher rate in this patient population. Future studies should include a control group of pediatric long-term tracheostomy patients without scoliosis and also stratify patients by degree of scoliosis to determine if there is a correlation between severity of spine curvature and tracheal abnormalities. Also, all tracheotomized patients with scoliosis, including syndromic versus non-syndromic patients, were studied. Subsequent studies should aim to separate these two groups to better gain an idea of the risk of tracheostomy-related complications in this diverse and special patient population.

CONCLUSIONS

A portion of patients with scoliosis who are tracheostomy-dependent have tracheostomy-related complications and anatomical abnormalities of the airway. Decannulation rates are also lower in this population compared to those seen in the literature. Further work is required to elucidate if the presence of scoliosis predisposes patients toward tracheostomy-related complications.

Acknowledgments

Huirong Zhu, PhD, for help with statistical analysis.

BIBLIOGRAPHY

1. Wilcox LJ, Weber BC, Cunningham TD, Baldassari CM. Tracheostomy complications in institutionalized children with long-term tracheostomy and ventilator dependence. *Otolaryngol Head Neck Surg* 2016;154:725–730. https://doi.org/10.1177/0194599816628486.
2. Trousdale WH, Boesch RP, Orvidas LJ, Balakrishnan K. Indirect management of full-thickness tracheal erosion in a complex pediatric patient. *Int J Pediatr Otorhinolaryngol* 2018;107:155–159. https://doi.org/10.1016/j.ijporl.2018.02.011.
3. Tweedie DJ, Cooke J, Stephenson KA, et al. Paediatric tracheostomy tubes: recent developments and our current practice. *J Laryngol Otol* 2018;132:961–968. https://doi.org/10.1017/S0022215118001330.
4. Naina P, Syed KA, Irodi A, John M, Varghese AM. Pediatric tracheal dimensions on computed tomography and its correlation with tracheostomy tube sizes. *Laryngoscope* 2020;130:1316–1321. https://doi.org/10.1002/lary.28141.
5. Pitcher G, Zaghal A, Sato Y, Shilyansky J. The thoracic inlet index in patients with tracheal obstruction caused by chest wall deformity: validation in patients and age-matched controls. *J Pediatr Surg* 2015;50:2028–2031. https://doi.org/10.1016/j.jpedsurg.2015.08.018.
6. Farrell J, Garrido E. Effect of idiopathic thoracic scoliosis on the tracheobronchial tree. *BMJ Open Respir Res* 2018;5:e000264. https://doi.org/10.1136/bmjresp-2017-000264.
7. Tatekawa Y, Muraji T. Surgical strategy for acquired tracheomalacia due to innominate artery compression of the trachea. *Eur J Cardio-Thorac Surg* 2011;39:412–413. https://doi.org/10.1016/j.ejcts.2010.08.012.
8. Tatekawa Y, Tojo T, Kanehiro H, Nakajima Y. Multistage approach for tracheobronchomalacia caused by a chest deformity in the setting of severe scoliosis. *Surg Today* 2007;37:910–914. https://doi.org/10.1007/s00595-007-3532-6.
9. Fujimoto Y, Hirose K, Ota N, et al. Suprasternal approach for impending tracheo-innominate artery fistula. *Gen Thorac Cardiovasc Surg* 2010;58:480–483; discussion 483-484. https://doi.org/10.1007/s11748-010-0598-7.
10. Kurose M, Takano K, Mitsuzawa H, Himi T. Tracheo-innominate artery fistula with severe motor and intellectual disability: incidence and therapeutic management. *Int J Pediatr Otorhinolaryngol* 2014;78:1348–1351. https://doi.org/10.1016/j.ijporl.2014.05.027.
11. Donnelly LF, Bisset GS. Airway compression in children with abnormal thoracic configuration. *Radiology* 1998;206:323–326. https://doi.org/10.1148/radiology.206.2.9457181.
12. Gu Y, Shelton JE, Ketchum JM, et al. Natural history of scoliosis in nonambulatory spastic tetraplegic cerebral palsy. *PM&R* 2011;3:27–32. https://doi.org/10.1016/j.pmrj.2010.09.015.
13. Reilly BK, Volk MS. Emergency use of a customized tracheostomy tube for pediatric patients. *Laryngoscope* 2012;122:1624–1625. https://doi.org/10.1002/lary.23267.
14. Chia AZH, Ng ZM, Pang YX, et al. Epidemiology of pediatric tracheostomy and risk factors for poor outcomes: an 11-year single-center experience. *Otolaryngol Head Neck Surg* 2020;162:121–128. https://doi.org/10.1177/0194599819887096.
15. Lubianca Neto JF, Castagno OC, Schuster AK. Complications of tracheostomy in children: a systematic review. *Braz J Otorhinolaryngol* 2020;S1808869420302470;20:S1808–8694. https://doi.org/10.1016/j.bjorl.2020.12.006.
16. Carr MM, Poje CP, Kingston L, Kielma D, Heard C. Complications in pediatric tracheostomies. *Laryngoscope* 2001;111:1925–1928. https://doi.org/10.1097/00005537-200111000-00010.
17. Richter A, Chen DW, Ongkasuwan J. Surveillance direct laryngoscopy and bronchoscopy in children with tracheostomies. *Laryngoscope* 2015;125:2393–2397. https://doi.org/10.1002/lary.25254.
18. Sharif-Askary B, Cheng TZ, Brown CS, Campbell JC, Yong Ji KS, Raynor EM. Airway findings in children with tracheostomies: when is diagnostic bronchoscopy and laryngoscopy indicated? *Int J Pediatr Otorhinolaryngol* 2019;117:73–77. https://doi.org/10.1016/j.ijporl.2018.11.021.
19. Gergin O, Adil E, Kawai K, Watters K, Moritz E, Rahbar R. Routine airway surveillance in pediatric tracheostomy patients. *Int J Pediatr Otorhinolaryngol* 2017;97:1–4. https://doi.org/10.1016/j.ijporl.2017.03.020.
20. Care of the Child with a Chronic Tracheostomy. This official statement of the American Thoracic Society was adopted by the ATS Board of Directors, July 1999. *Am J Respir Crit Care Med* 2000;161:297–308. https://doi.org/10.1164/ajrccm.161.1.ats1-00.
21. Tanaka M, Watanabe Y, Fukushima K, Fujiwara T, Yagi K, Ohta S. Fatal stenosis of trachea and main bronchus due to compression by the spine and sternum in three patients with severe motor and intellectual disabilities. *No Hattatsu Brain Dev* 2001;33:347–350.
22. Taniguchi Y, Matsubayashi Y, Kato S, et al. Tracheal stenosis due to cervicothoracic hyperlordosis in patients with cerebral palsy treated with posterior spinal fusion: a report of the first two cases. *BMC Musculoskelet Disord* 2021;22:217. https://doi.org/10.1186/s12891-021-04094-y.
23. Lee DJ, Yang W, Propst EJ, Rosenblatt SD, Hseu A, Wolter NE. Tracheo-innominate fistula in children: a systematic review of literature. *Laryngoscope* 2020;130:217–224. https://doi.org/10.1002/lary.27765.
24. Tsugawa C, Ono Y, Nishijima E, Takamizawa S, Satoh S, Muraji T. Transection of the innominate artery for tracheomalacia caused by persistent opisthotonus. *Pediatr Surg Int* 2004;20:55–57. https://doi.org/10.1007/s00383-003-1082-6.
25. Salley J, Kou Y, Shah GB, Mitchell RB, Johnson RF. Survival analysis and decannulation outcomes of infants with tracheotomies. *Laryngoscope* 2020;130:2319–2324. https://doi.org/10.1002/lary.28297.
26. Kolb CM, Halbert K, Xiao W, Strang AR, Briddell JW. Comparing decannulation failures and successes in pediatric tracheostomy: an 18-year experience. *Pediatr Pulmonol* 2020;17. https://doi.org/10.1002/ppul.25170.
27. Ha T-A, Goyal M, Ongkasuwan J. Duration of tracheostomy dependence and development of tracheocutaneous fistula in children: TC fistula and duration of tracheostomy. *Laryngoscope* 2017;127:2709–2712. https://doi.org/10.1002/lary.26718.
28. Carron JD, Derkay CS, Strope GL, Nosonchuk JE, Darrow DH. Pediatric tracheotomies: changing indications and outcomes. *Laryngoscope* 2000;110:1099–1104. https://doi.org/10.1097/00005537-200007000-00006.
29. Ogilvie LN, Kozak JK, Chiu S, Adderley RJ, Kozak FK. Changes in pediatric tracheostomy 1982-2011: a Canadian tertiary children's hospital review. *J Pediatr Surg* 2014;49:1549–1553. https://doi.org/10.1016/j.jpedsurg.2014.04.014.
30. Dursun O, Ozel D. Early and long-term outcome after tracheostomy in children. *Pediatr Int* 2011;53:202–206. https://doi.org/10.1111/j.1442-200X.2010.03208.x.